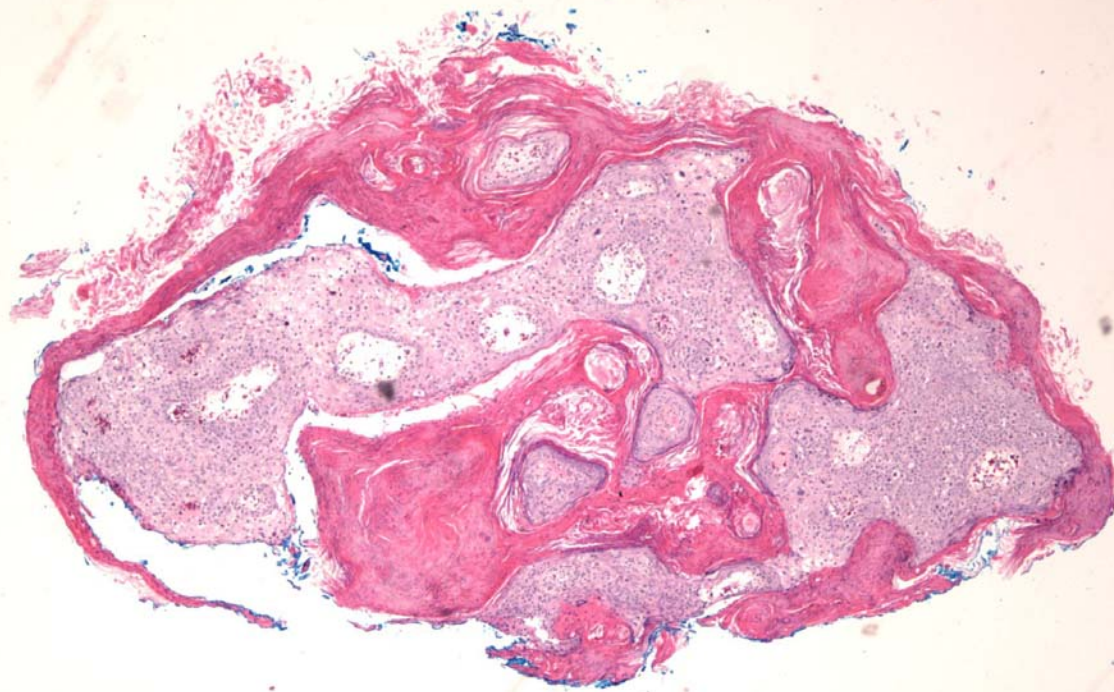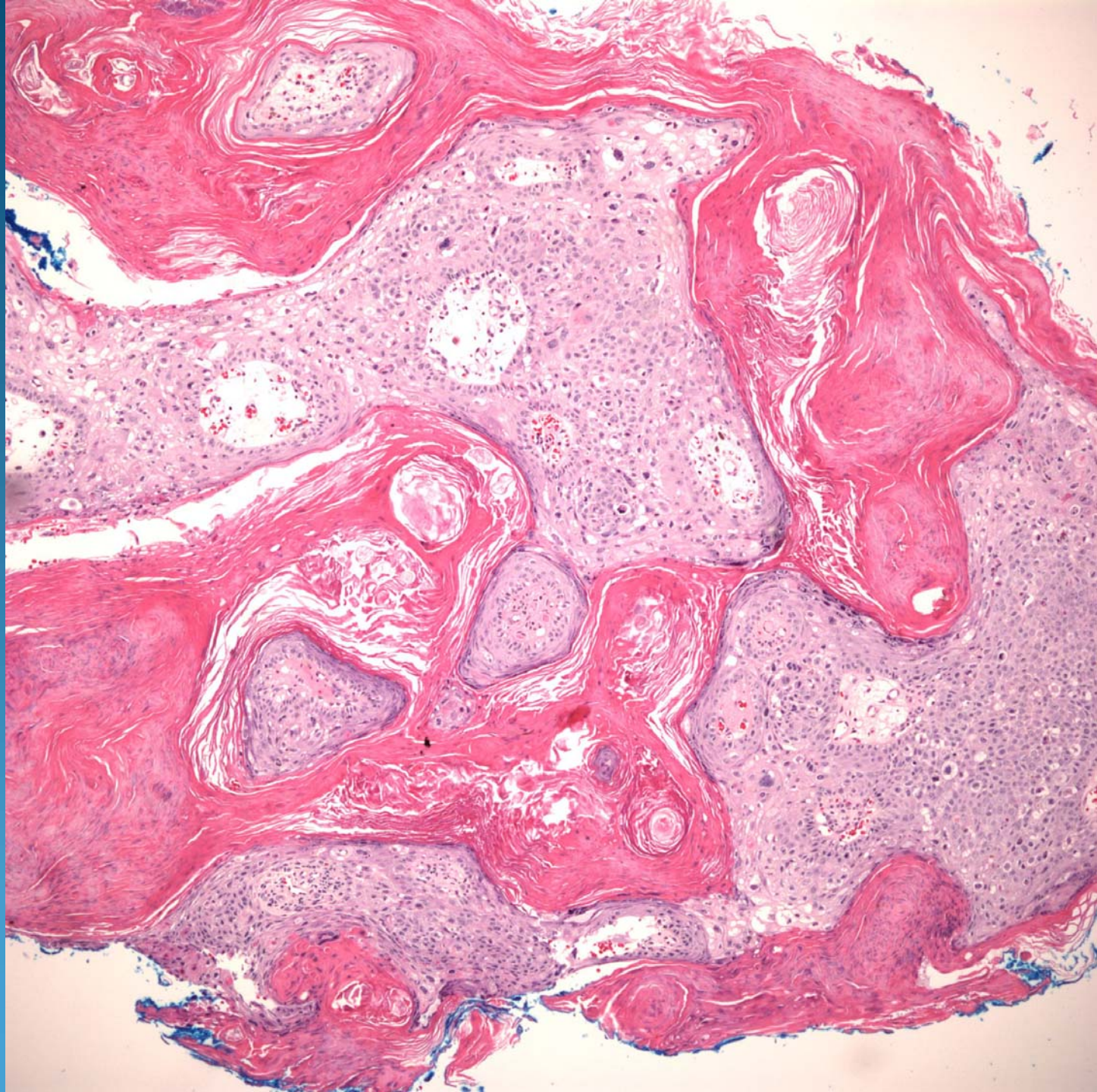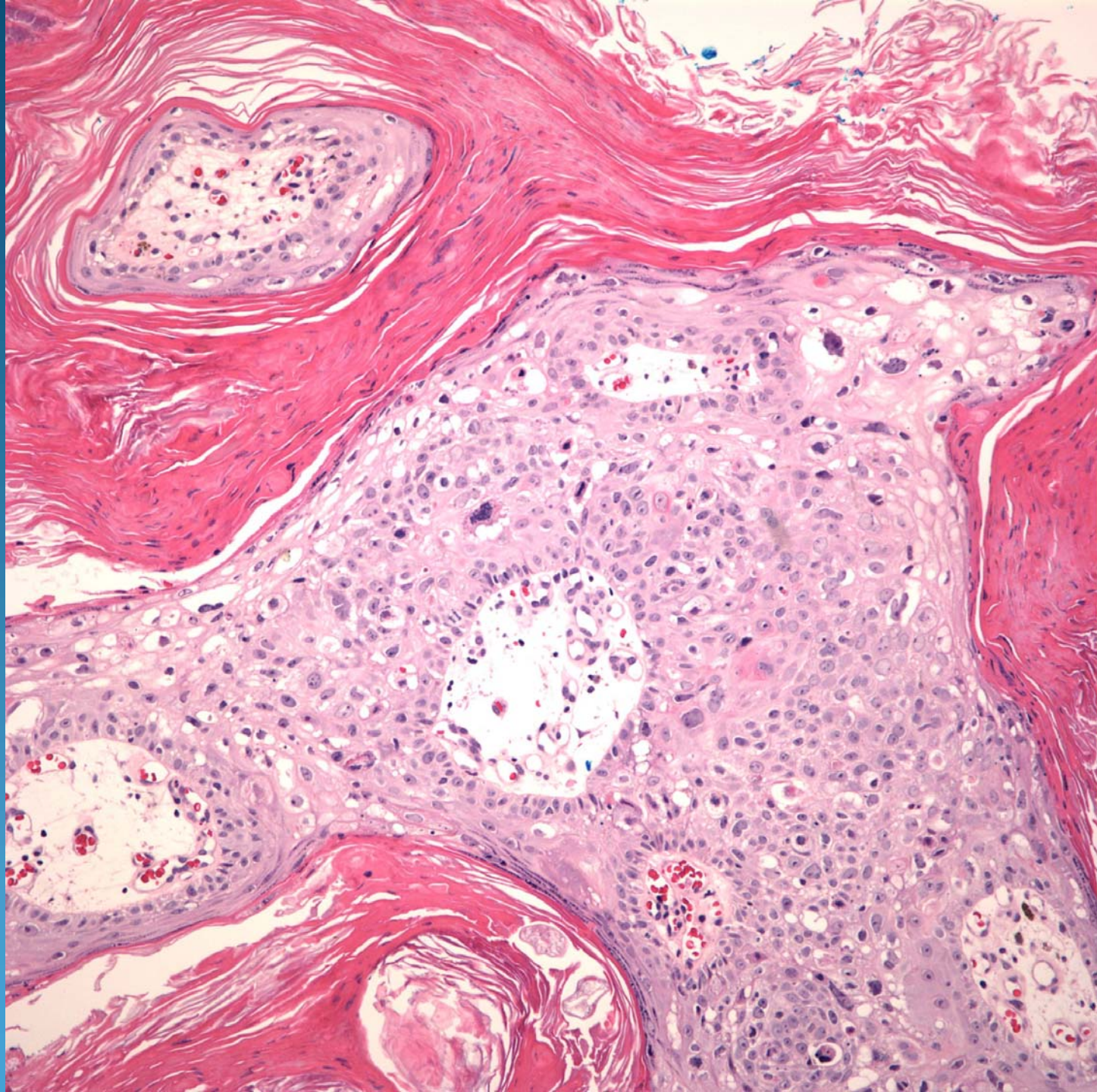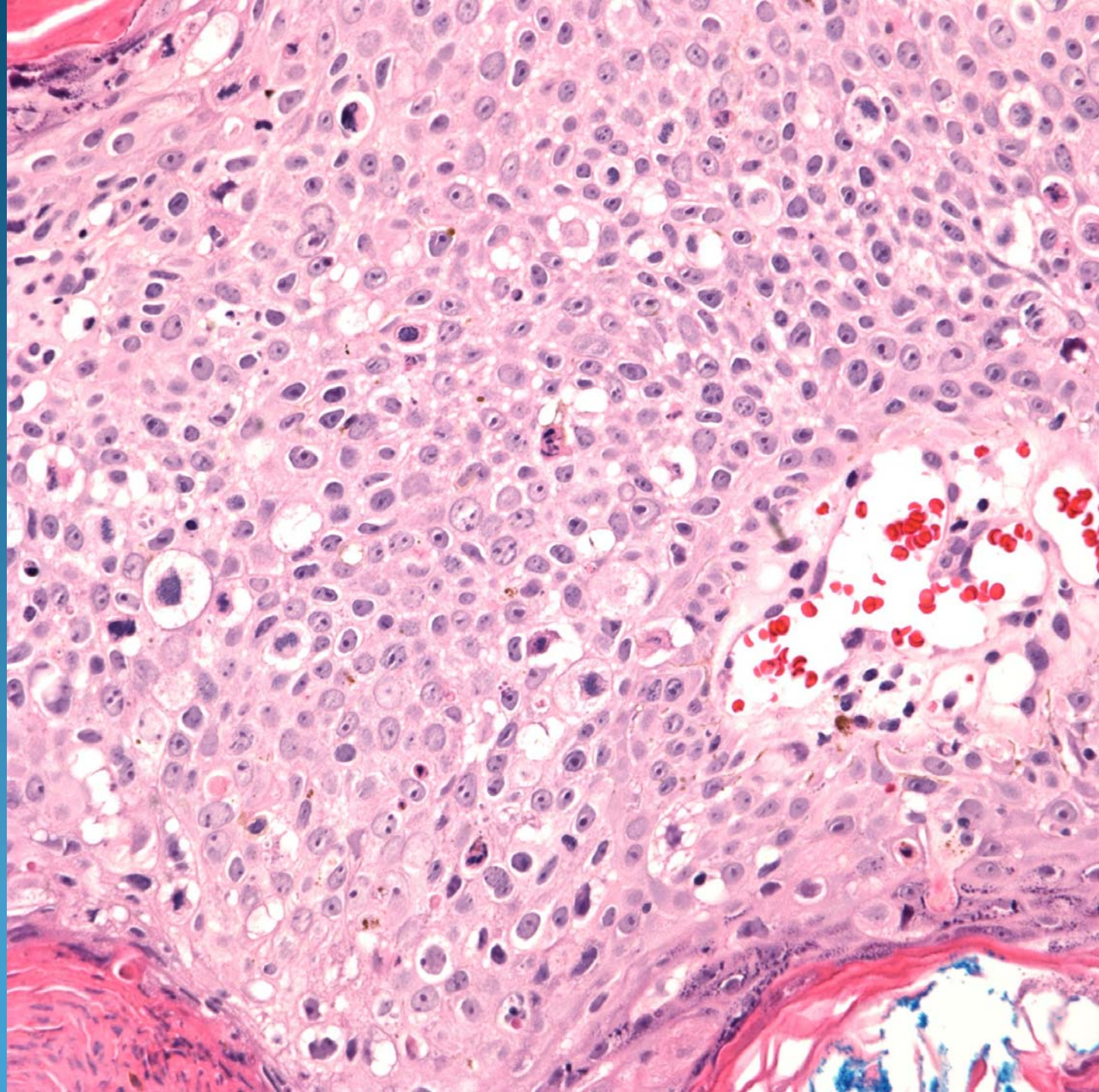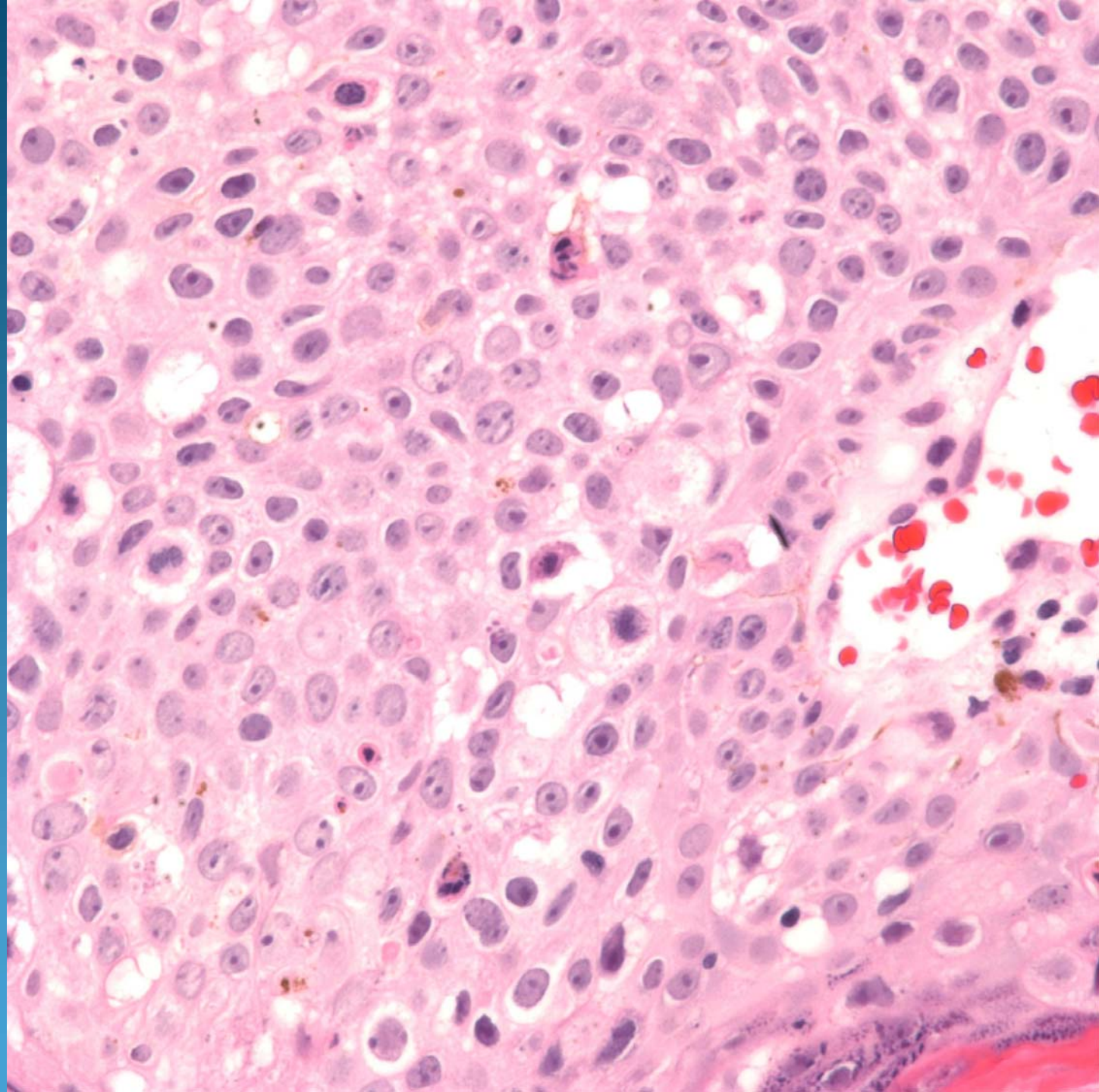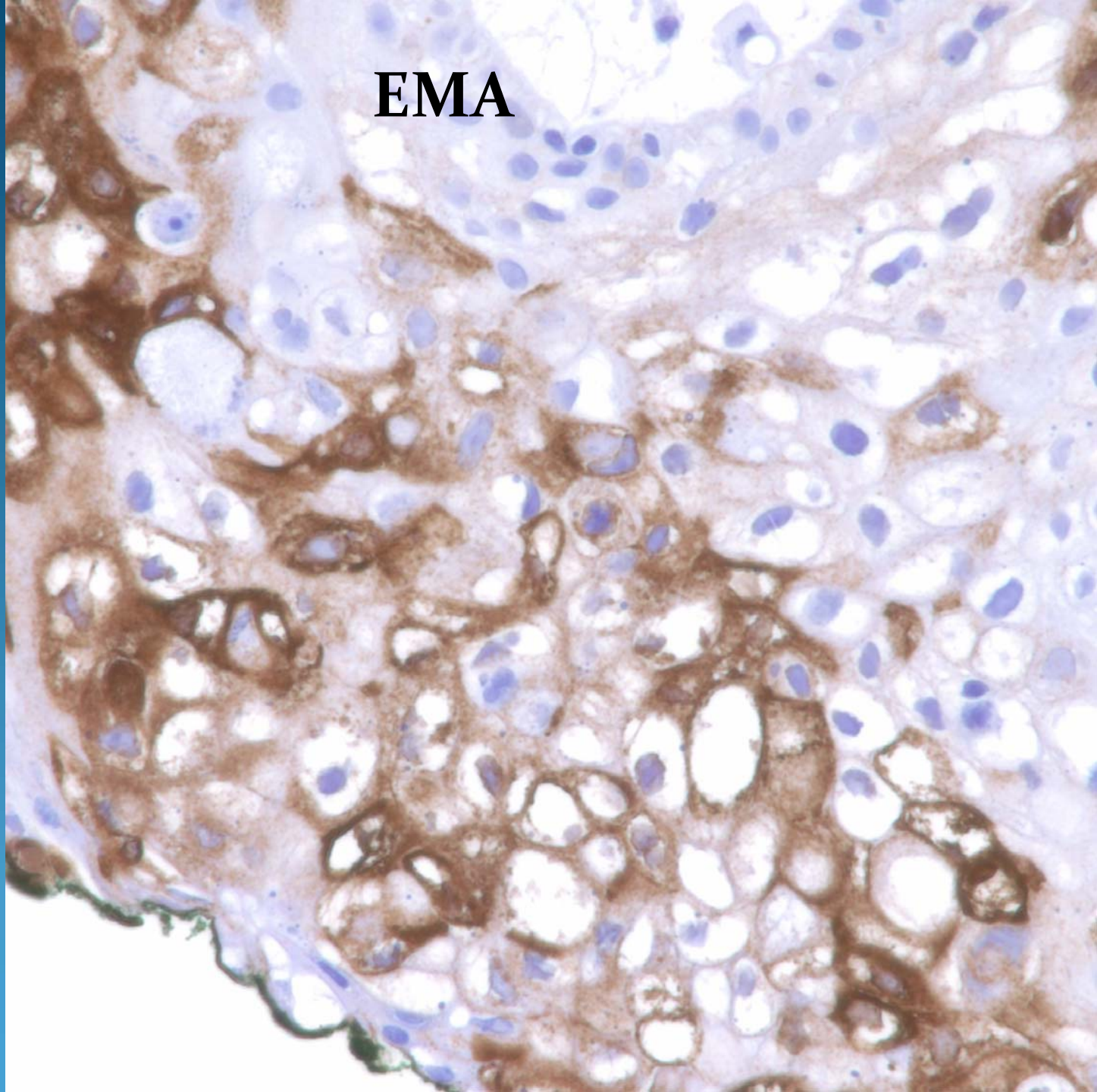


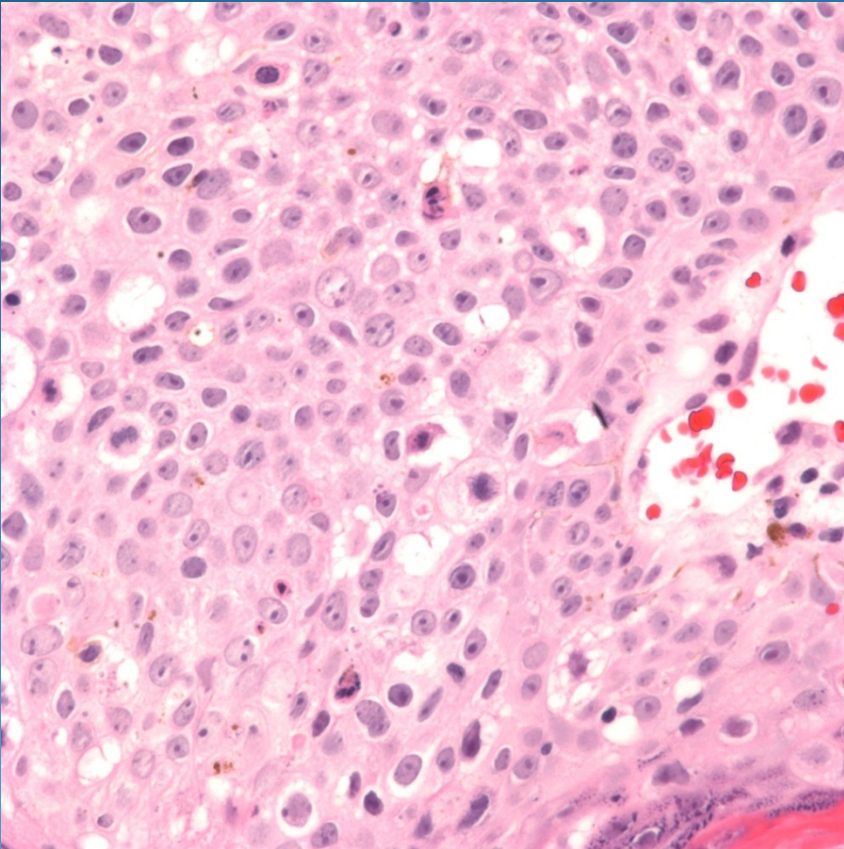


**EMA**



# Sebaceous Carcinoma

# Pearls



- Cytologically malignant epithelial cells with sebaceous differentiation
- Cytoplasmic vacuoles indenting nuclei
- May confirm with EMA stain
- High clinical suspicion with malignant lesions from the eyelid